

# Utilizing Long Short-Term Memory for Detecting Multiple Sclerosis Based on Vessel Analysis

Neda Yaghoubi<sup>a</sup>, Hassan Masumi<sup>a</sup>, Mohammad Hossein Fatehi<sup>b</sup>, Fereshteh Ashtari<sup>c</sup>, Rahele Kafieh<sup>\*d,e</sup>

<sup>a</sup>Department of Biomedical Engineering, Kazerun Branch, Islamic Azad University, Kazerun, Iran

<sup>b</sup>Department of Electrical Engineering, Kazerun Branch, Islamic Azad University, Kazerun, Iran

<sup>c</sup>Isfahan neurosciences research center, Isfahan University of Medical Sciences, Isfahan, Iran

<sup>d</sup>School of Advanced Technologies in Medicine, Medical Image & Signal Processing Research Center, Isfahan University of Medical Sciences, Isfahan, and Iran

<sup>e</sup>Department of Engineering, Durham University, South Road, Durham, UK

Corresponding author email: rkafieh@gmail.com

Received: Feb. 02, 2024, Revised: May 04, 2024, Accepted: May 06, 2024, Available Online: May 08, 2024,  
DOI: 10.61186/ijop.17.1.103

**ABSTRACT— Background:** Multiple Sclerosis (MS) is a chronic immune-mediated disease affecting the central nervous system, leading to various disturbances, including visual impairment. Early and accurate diagnosis of MS is critical for effective treatment and management. Scanning Laser Ophthalmoscopy (SLO) is a non-invasive technique that provides high-quality retinal images, serving as a promising resource for the early detection of MS. This research investigates a vessel-based approach for MS detection in SLO images using Long Short-Term Memory (LSTM) networks.

**Material and Methods:** A total of 106 Healthy Controls (HCs) and 39 MS patients (78 eyes) were enrolled. After implementing quality control measures and removing poor-quality or damaged images, the research utilized a total of 265 photos (73 MS and 192 HC). An approach for the early detection of MS in SLO images using LSTM network is introduced. This approach involves two steps: 1. It involves pre-processing and extracting vessels and then pre-training a deep neural network using the source dataset, and 2. tuning the network on the target dataset of SLO images.

The significance of vessel segmentation in MS detection is examined, and the application of the proposed method in improving diagnostic models is explored. The proposed approach

achieves an accuracy rate of 97.44% when evaluated on a test dataset consisting of SLO pictures.

Through experiments on SLO datasets and employing the proposed vessel-based approach with LSTM, empirical results demonstrate that this approach contributes to the early detection of MS with high accuracy. These models exhibit the capability to accurately detect the disease with high precision and appropriate sensitivity.

**KEYWORDS:** Multiple Sclerosis, Scanning Laser Ophthalmoscopy, Vessel, Segmentation, Machine Learning, LSTM.

## I. INTRODUCTION

Multiple Sclerosis (MS) is a chronic autoimmune disorder that affects the central nervous system (CNS) and manifests in a diverse array of symptoms, including visual impairment [1]. The condition is distinguished by the presence of inflammation, demyelination, and impairment of nerve fibers, leading to disturbances in the transmission of nerve signals over the whole of the body. The rapid identification and precise diagnosis of MS are of paramount importance in order to facilitate the prompt implementation of suitable treatment approaches and to successfully

manage the development of the illness [3]–[4]. Regrettably, the diagnosis of multiple sclerosis MS presents challenges due to the resemblance of its symptoms to those of other neurological disorders, and the absence of a singular conclusive test for MS [3].

Scanning Laser Ophthalmoscopy (SLO) has been recognized as a non-invasive imaging modality that provides high-resolution retinal pictures, offering vital information on the condition of retinal vasculature and other retinal structures. Individuals with MS may have distinct alterations and irregularities in the retina, which is considered an extension of the CNS. Hence, the use of SLO images has emerged as a potentially valuable resource in facilitating the timely identification and assessment of MS. Through a meticulous analysis of the retinal vasculature and other retinal characteristics using SLO pictures, it is possible to identify potential biomarkers and indications of disease associated with multiple sclerosis [4].

Multiple methodologies have been suggested for the identification of multiple sclerosis in scanning laser ophthalmoscopy pictures, with particular emphasis on machine learning-based techniques. The aforementioned techniques use sophisticated algorithms to extract pertinent characteristics from retinal pictures, including texture, morphology, and intensity patterns. These characteristics are then employed for the purpose of classifying and identifying alterations associated with multiple sclerosis. Nevertheless, the goal of precisely identifying multiple sclerosis using SLO pictures continues to pose difficulties owing to the intricate nature of the image data and the substantial variations in retinal characteristics across diverse people. As a consequence, some methodologies may encounter constraints in terms of precision and responsiveness, impeding their capacity to attain consistent and dependable mass spectrometry detection outcomes [5]–[8].

It is crucial to prioritize the resolution of these difficulties in order to fully use the promise of SLO in the identification of multiple sclerosis. The utilization of advanced machine learning

methodologies, in conjunction with intricate feature extraction procedures and expansive, varied datasets, exhibits the potential to augment the precision and resilience of MS identification from scanning laser ophthalmoscopy pictures. Through ongoing refinement and optimization of these methodologies, scholars and medical practitioners have the ability to fully harness the potential of SLO as a helpful instrument in the timely identification and treatment of MS, eventually resulting in enhanced patient outcomes and a more comprehensive comprehension of this intricate neurological condition [5]–[7]–[9].

comparison between Uveitis and Optic Neuritis (ON), Optic neuritis refers to inflammation of the optic nerve, which is responsible for transmitting visual information from the eye to the brain.

It often presents with acute onset of visual symptoms such as decreased vision, pain with eye movement, and changes in color perception. Optic neuritis can affect one or both eyes and may lead to temporary or permanent visual impairment. In MS, optic neuritis is a common manifestation, occurring in approximately 20–30% of patients. It typically manifests as unilateral optic neuritis, affecting one eye initially, but it can also be bilateral in some cases.

Intermediate Uveitis Intermediate uveitis, also known as Pars Planitis, is inflammation of the middle layer of the eye (uvea), specifically the area known as the pars Plana. It typically presents with inflammation in the vitreous humor (the gel-like substance in the middle of the eye) and may involve other structures such as the retina and optic nerve head. Symptoms of intermediate uveitis can include floaters (dark spots or lines in the vision), blurred vision, and eye pain. While intermediate uveitis can occur in MS patients, it is less common compared to optic neuritis.

In summary, while both optic neuritis and intermediate uveitis are ocular complications associated with MS, optic neuritis involves inflammation of the optic nerve and is characterized by visual symptoms, whereas

intermediate uveitis involves inflammation of the uvea and may present with symptoms such as floaters and blurred vision. Both conditions can affect the appearance of the retina and can be assessed using techniques such as SLO ophthalmoscopy. [26]–[2]

In [10], conducted a meta-analysis of existing studies utilizing retinal imaging to assess vascular changes in MS patients, employing machine learning techniques for data synthesis and pattern recognition. They synthesized findings from multiple sources, confirming consistent micro vascular alterations across different studies. The meta-analysis provided a broader perspective on the cumulative evidence. In [11] dynamic contrast-enhanced MRI to investigate blood-brain barrier permeability and correlated these findings with retinal vascular changes in MS patients. They employed machine learning algorithms for data fusion and analysis. They identified associations between blood-brain barrier disruption and retinal vessel alterations, suggesting a systemic vascular component in MS. In [12] OCTA to compare retinal vascular alterations in different subtypes of MS. They found subtype-specific variations in vessel density, potentially indicating distinct disease mechanisms. The study's subgroup analysis, along with AI-based image analysis, contributed to personalized treatment strategies. In [13] a machine learning approach, specifically deep neural networks, to classify retinal vascular patterns in MS patients based on OCTA data. Their algorithm achieved high accuracy in distinguishing MS patients from controls, demonstrating the potential diagnostic utility of retinal imaging. The present study examines a strategy that utilizes retinal vessels for the identification of MS in SLO pictures. The approach employs Long Short-Term Memory (LSTM) networks, which are a form of recurrent neural network RNN. [9]–[18]–[20]. The process of demyelination hinders the transmission of electrical impulses, leading to the manifestation of diverse symptoms resulting from spinal inflammation. The timely identification of this ailment is crucial for halting illness advancement and enhancing patients' quality of life.

Spectral-domain optical coherence tomography (SD-OCT) is a prevalent medical imaging modality that utilizes laser light to acquire high-resolution retinal pictures. Spectral-domain optical coherence tomography (SD-OCT) pictures provide exceptional resolution and accuracy in seeing minute details of retinal microstructures. The use of SLO, as a non-invasive modality, is well-suited for a wide range of medical applications in routine clinical practice, including its potential use in the identification of multiple sclerosis [10].

In SLO pictures, retinal arteries are seen as interconnected linear structures responsible for transporting blood from various regions of the retina toward its central region. Alterations in the process of vessel segmentation have the potential to serve as an indicator of the existence of neurological disorders, such as MS. Hence, the identification of diverse vessel patterns may contribute to the timely diagnosis of Multiple Sclerosis [12].

LSTM networks are a kind of recurrent neural networks that have shown efficacy in addressing intricate temporal tasks. These networks possess the capacity to both keep and discard long-term information, making them very valuable in the analysis of medical imagery. LSTM, owing to its capacity for acquiring long-term patterns, exhibits the capability to identify intricate patterns within SLO pictures, hence presenting potential use in the early identification of multiple sclerosis [10]–[13].

The above material outlines a suggested methodology for the early diagnosis of MS in SLO pictures. This strategy involves the use of LSTM networks. This essay makes two significant contributions:

1. It involves pre-processing and extracting vessels and then pre-training a deep neural network using the source dataset. During this stage, the deep neural network is trained using datasets that pertain to several additional illnesses. The neural network has the capability to acquire knowledge about general and prevalent patterns inside medical pictures.

2. The network will undergo fine-tuning using the target dataset consisting of SLO pictures. During this phase, the LSTM networks undergo fine-tuning using the SLO datasets.

The rest of the paper is structured as follows: The data set is introduced and our suggested solution is thoroughly explained in Section 2. The experiment's findings are presented in Section 3. The results of our experiment are presented in Section 4. Finally, the paper is concluded in Section 5.

## II. MATERIAL AND METHODS

### A. Dataset

The Kashani Comprehensive MS Center in Isfahan, Iran collected a dataset of SLO images between April 2017 and March 2019[25]. This dataset contained images of the eyes of both MS patients and healthy individuals, who were matched for age and gender. The Isfahan University of Medical Sciences' ethical committee approved the data collection process, which adhered to the Declaration of Helsinki. A professional used an SD-OCT and Heidelberg Eye Explorer (HEYEX) version 5.1 to produce the pictures. The dataset consists of 106 Healthy Controls (HCs) and 39 MS patients (78 eyes), and after quality control measures were taken and poor quality or damaged images were removed, the research utilized a total of 265 photos (73 MS and 192 HC).

### B. Data Preprocessing and Segmentation

The preprocessing and segmentation method utilized in this article involves standardizing images using the Tyler's algorithm along with discrete wavelet transform. In this approach, input data such as SLO images undergo preprocessing and segmentation before entering the models, and retinal vessels are extracted from the images. By doing so, the data are transformed into a standardized and interactive format for the model, which may aid in improving the training of models with better accuracy and higher speed, ultimately leading to enhanced performance. This preprocessing and segmentation method

could bring significant improvements in the model's performance for detecting healthy and diseased individuals as discussed in the article.

Data preprocessing refers to the first step in data analysis when raw data is transformed and prepared for further analysis. This procedure involves several techniques. Initially, the dataset was partitioned into two distinct subgroups: one designated for the development of the algorithm, often referred to as the training set, and another intended for the assessment of the algorithm's performance, known as the validation set. The process of normalizing numerical features begins with the normalization of the training set, whereby the mean is adjusted to 0 and the standard deviation is set to 1. This normalization procedure is then extended to the validation set, using the mean and standard deviation values derived from the training set. This technique assumes that algorithms are not provided with access to future knowledge. In order to accommodate machine learning algorithms that operate only on numerical data, the categorical characteristics were transformed into numerical values by the use of one-hot encoding.

The objective of this research was to assess the effectiveness of several classification algorithms in differentiating between individuals without any health conditions and those diagnosed with MS, as well as predicting the development of impairment in MS patients. The methods used in this study included, the utilization of LSTM and Convolutional Neural Network (CNN) models.

**Model 1:** Model 1 is a serial model, also known as a Sequential model, composed of several layers with different functionalities. The architecture of this model is as follows:

**Reshape Layer:** This layer is a reshape layer that rearranges the model's inputs into a shape of (None, 50176, 3). Here, "None" represents

the batch size, which is determined during runtime, 50176 indicates the number of input features, and 3 represents the number of channels in each feature (in this case, 3 channels corresponding to RGB colors).

**LSTM Layer:** The LSTM layer is a LSTM layer with 64 nodes in the output. LSTM is known for its suitability for sequential data and its ability to retain time-dependent information within the data.

**Dense Layers:** These layers are dense layers that utilize the output from the LSTM layer. First, there is a dense layer with 128 nodes, followed by another dense layer with 1 node (representing the final output of the model). These layers are responsible for transforming the output features from the LSTM layer into the final output of the model.

The total number of parameters in the model is 25,857, and all parameters are trainable, meaning they can be updated during the training process. This specific model is designed for a particular task that involves sequential data and utilizes the LSTM layer to handle time-dependent data.

### C. LSTM MODEL

A Recurrent Neural Network (RNN) is a kind of artificial neural networks specifically designed for the purpose of analyzing and manipulating sequential input. In contrast to conventional feed forward neural networks, RNNs possess a distinctive capability to catch patterns and interdependencies within sequential input. This is achieved by the maintenance of a hidden state, which retains information from preceding stages.

### D. Data augmentation

Given the scarcity of accessible data, it is essential to use data augmentation methodologies in order to expand the training set and mitigate the risk of over fitting. Two data augmentation strategies were chosen after conducting trials with several methods for enhancing the data, as shown below:

RNNs have become a basic tool in the domain of deep learning, especially for tasks that involve the interpretation of sequential input. The LSTM is a variant of the RNNs model that specifically tackles the issue of the vanishing gradient problem. This analysis explores the internal mechanisms of LSTM units, including the input, forget, and output gates. These gates facilitate the network's ability to acquire knowledge and retain information pertaining to distant relationships within sequential data. The LSTM is a specific design of RNNs that has shown considerable efficacy in a range of tasks involving sequences, such as the processing of medical data. MS is a neurological condition that affects the central nervous system, and the earliest identification of its onset is of utmost importance for prompt intervention and effective treatment. LSTM may be used as a computational method for identifying patterns within medical data, which may potentially serve as indicators for the existence of MS (Fig. 1).

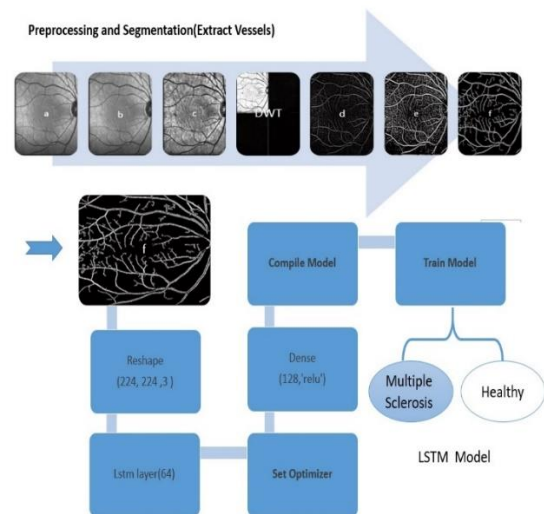


Fig. 1. The architecture of model based LSTM

**Random Rotation (0.2):** The process of random rotation is performed on every picture, wherein a maximum rotation angle of 0.2 radians is applied. The aforementioned method incorporates minor random rotations into the original photos, introducing further changes to the dataset and augmenting the model's capacity for generalization.

**Random Zoom (0.2):** The process of random zooming involves the application of a random

scaling factor ranging from 0.2 to each individual picture. The use of this augmentation strategy facilitates the model's acquisition of knowledge from both magnified and reduced versions of the pictures, resulting in enhanced resilience in the identification of objects of varying sizes.

The process of horizontal mirroring, which is often referred to as flipping, involves the reflection of each picture along a horizontal axis. This strategy is very efficient in augmenting the training set by increasing its size twofold, hence facilitating the model's ability to acquire knowledge from horizontally mirrored renditions of the original pictures. Figure 2 depicts an exemplification of the photographs before to and subsequent to the use of data augmentation techniques. The graphic illustrates that the use of data augmentation provides supplementary variety into the training set, hence enhancing the model's capacity to generalize well to unknown data. Figure 2 show SLO images obtained by different data augmentation methods, original SLO image, horizontal and mirroring random rotation. [25]

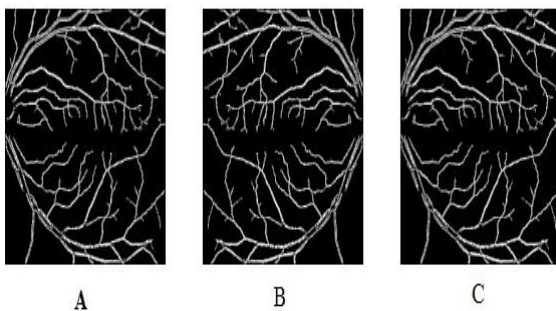


Fig. 2. SLO images obtained by different data augmentation methods: (A) original SLO image; (B) horizontal; (C) mirroring random rotation (0.2)

### III. RESULTS

In the first phase, preprocessing and segmentation outputs for original input image and proposed method are show in Fig. 3.

The study employs LSTM and CNN models for classification and detection on the current dataset, with results reported accordingly. Despite examining various models on the mentioned dataset, due to data limitations, they

did not demonstrate satisfactory performance. Therefore, images are randomly divided into two groups: validation and training, and the networks are trained. Figure 5 illustrates the training and validation accuracy for these two methods, while Fig. 6 depicts the Heat map of LSTM layer weights.

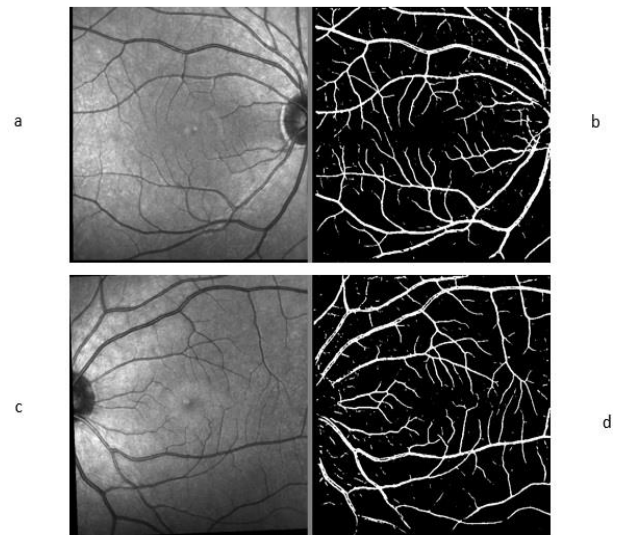


Fig. 3. Preprocessing and Segmentation outputs. (a, c) Original input image. (b, d) Proposed method.

Table 1. LSTM Model: sequential\_5

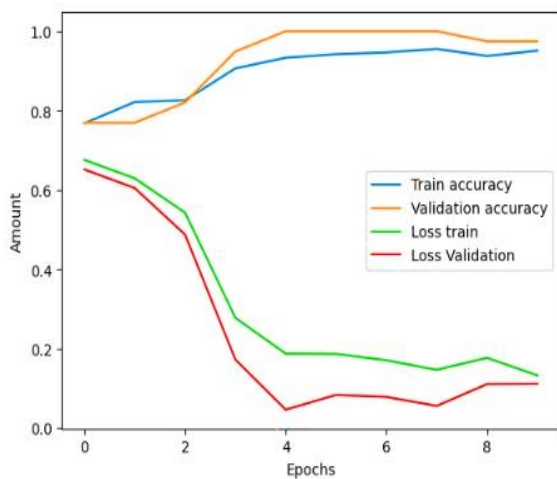
Layer (type)	Output Shape	Param
reshape_4 (Reshape)	(None, 50176, 3)	0
lstm_4 (LSTM)	(None, 64)	17408
dense_8 (Dense)	(None, 128)	8320
dense_9 (Dense)	(None, 1)	129
<b>Total params: 25,857; Trainable params: 25,857; non-trainable params: 0</b>		

In Tables 1 and 2, the measurement parameters of the models for the given problem are presented with precision. In Table 1 the parameters for LSTM model are shown. These parameters include metrics used to evaluate the performance of models, and further details can be found in the tables. These metrics encompass both trainable and non-trainable parameters, as well as layer features, aimed at providing a precise evaluation of the model's performance

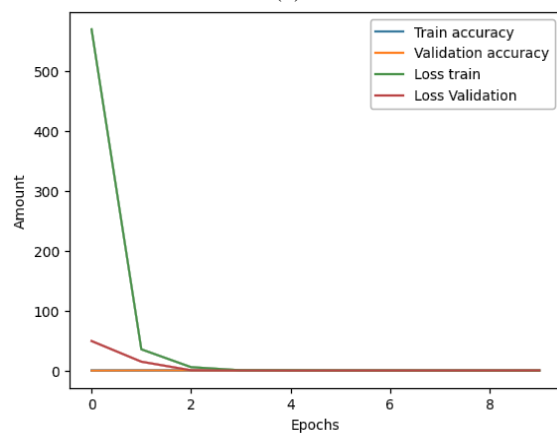
in disease detection or the examined problem. Figure 4 shows the Training and Validation Accuracy for this two methods and Fig. 5 show Heat map of LSTM Layer weight.

Table 2. CNN Model

Value	Property
Simple CNN with three convolutional layers and two fully connected layers	Model Architecture
Total Parameters	11,169,089 (approximately 42.61 megabytes)
Trainable	Yes
Trainable Parameters	Yes
Non-trainable Parameters	Zero
Loss Function	binary_crossentropy
Optimizer	Adam with learning rate of 0.01



(a)



(b)

Fig. 4. Training and Validation Accuracy, (a) LSTM and (b) CNN.

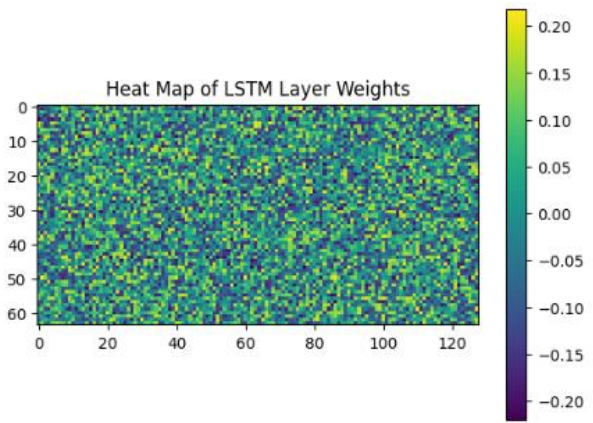


Fig. 5. Heat map of LSTM Layer weight

Utilizing Fig. 5 in the article to present feature maps or Heat map for highlighting regions of higher importance detected by the network is highly beneficial. These maps are applied over the image to depict more important areas with warm colors such as red and orange, while less important areas are represented with cool colors like blue. This color combination indicates the level of significance of each region in the network's decision-making process. Consequently, these maps assist researchers and medical practitioners in easily identifying and interpreting the more crucial areas in the image, which can be highly effective in disease detection and treatment, such as in the case of MS.

The Receiver Operating Characteristic (ROC) curve is used to evaluate the performance of a binary classification model. The assessment of a model's ability to discern between two distinct groups or categories, sometimes denoted as positive and negative instances, is a commonly used approach. The use of ROC curves is very valuable in scenarios where the classification model produces probability-based outputs or when it is necessary to evaluate the model's performance at different categorization thresholds. The ROC curve is a graphical representation that illustrates the relationship between sensitivity (true positive rate) and specificity (1-specificity) across various threshold values [33]. The ROC curve is widely used in several fields, including but not limited to medical diagnostics, machine learning, and signal identification. This technique assists researchers and practitioners in selecting an

ideal threshold that balances sensitivity and specificity, therefore addressing the particular requirements and constraints of the application [35].

The use of the region under the ROC curve, also known as Area under the Curve (AUC), is a widely used metric applied to statistically evaluate the overall effectiveness of the model. A higher value of the AUC indicates a stronger ability of the model to discriminate, while an AUC value of 0.98 suggests that the model's performance is similar to that expected by chance. According to Fig. 6b, Validation Loss is 0.5402 and Validation Accuracy is 0.7949 and AUC is 0.67 for CNN.

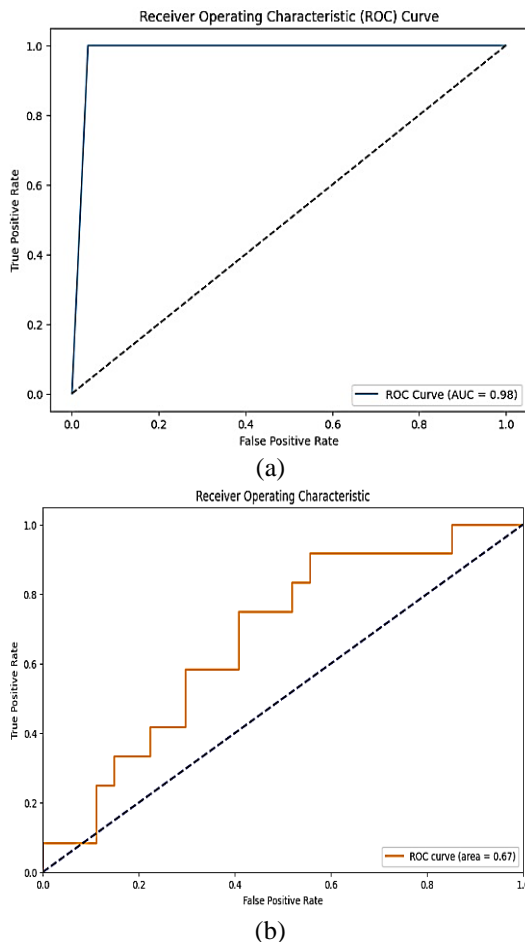


Fig. 6. Receiver Operating Characteristic for (a) LSTM and (b) CNN.

The Figs. 6(a) and 6(b) in this study illustrates the correlation between two variables. The true positive rate, sometimes referred to as sensitivity or recall, pertains to the ratio of properly recognized true positives by a diagnostic test or classification model. The

false positive rate pertains to the ratio of false positive outcomes inside a diagnostic test or statistical model. The error rate of the test or model is a metric used to quantify the degree of inaccuracies present. This article examines the inclination towards a positive slope in the curve, which signifies a favorable value and reflects the efficacy of the model.

In conclusion, the LSTM model outperforms the CNN model in terms of accuracy and overall performance in this classification task. It demonstrates better capability to correctly identify positive cases and has a more balanced trade-off between precision and recall. On the other hand, the CNN model struggles with positive case identification and shows a less balanced performance.

Below is the complete interpretation of the evaluation results for the model on the validation dataset after Fine-tuning:

**Confusion Matrix:** The confusion matrix provides a visual representation of the accuracy of a classification model by displaying the number of samples that were correctly and mistakenly predicted for both the positive and negative classes. The entries along the diagonal of this matrix correspond to the accurate predictions made for both the positive class (consisting of 27 samples) and the negative class (comprising 11 examples). The components located outside the main diagonal of the matrix correspond to the quantity of inaccurate forecasts.

$$\text{Confusion M Matrix} = \begin{bmatrix} 27 & 0 \\ 0 & 11 \end{bmatrix}$$

**Accuracy:** Accuracy may be defined as the proportion of accurately predicted samples to the overall number of samples. With an accuracy of 0.9744, the model has correctly classified approximately 97.44% of the samples. This indicates a very good performance of the model in overall correctness. Also, we ran the model with method CNN and its accuracy was 0.64.



**Precision:** Precision may be defined as the proportion of accurately predicted positive samples to the overall number of samples that the model has forecasted as positive. With a precision of 0.9231, the model has correctly predicted all the samples that are truly positive.

**Recall:** Recall is the ratio of correctly predicted positive samples to the total number of positive samples in the dataset. With a recall of 1, the model has correctly identified approximately 100% of all positive samples. Compared to LSTM, the value of Recall in method CNN became 0.33.

**F1 Score:** The F1 Score is a composite metric that encompasses both accuracy and recall, hence achieving a harmonious equilibrium between these two performance measures. With an F1 Score of 0.96, the model exhibits high performance in generalization to unknown data and strikes a good balance between precision and recall. Compared to LSTM, the value of Recall in method CNN became 0.364.

**AUC Score:** The AUC Score is a metric that quantifies the extent of discrimination between positive and negative classes by measuring the area under the ROC Curve. With an AUC Score of 0.98, the model demonstrates a good capability in distinguishing between positive and negative samples. Compared to LSTM, the value of Recall in method CNN became 0.55.

The table3 and Fig. 7 shows the performance metrics of both LSTM and CNN models. As we can see, the LSTM model outperforms the CNN model in terms of accuracy, precision, recall, F1 score, and AUC score. It demonstrates higher overall performance in the classification task. However, the CNN model has a perfect precision, but it struggles with low recall, indicating that it has difficulty identifying positive cases correctly. The LSTM model, on the other hand, achieves a balanced F1 score, which demonstrates a good trade-off between precision and recall. Additionally, the LSTM model shows a higher AUC score, indicating its better ability to discriminate between positive and negative cases. Figure 8 displays the box plots.

Table 3. Performance metrics of both LSTM and CNN models

Model	Accuracy	Precision	Recall	F1Score	AUC Score
LSTM	0.9744	0.9231	1	0.96	0.98
CNN	0.64	0.4	0.333	0.364	0.55

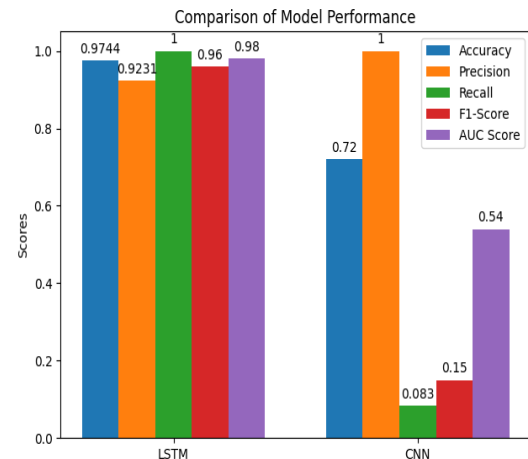


Fig. 7. Performance metrics of both LSTM and CNN models

The box plots have been constructed to provide a comparative examination of the efficacy of many machine learning models under diverse conditions and alterations to the data. Now the boxplots in Fig. 8 compare the validation with LSTM different Machine Learning models for HOG and 17 Feature Extract.

The horizontal axis of the map illustrates many models, with each model being graphically shown as a box. The accuracy values of the models are shown on the vertical axis. The box is divided into two compartments: the upper compartment represents a range including 50% of the data, while the line included inside the box represents the median accuracy of the model. In addition, the boxplot is accompanied with whiskers, which are used to depict the top and lower limits of accuracy. Outliers are data points that are outside the whiskers, indicating observations that deviate from the expected range.

## IV. DISCUSSION

Artificial Intelligence (AI) has made significant strides in the realm of healthcare, including the diagnosis and management of diseases like

(MS). In the context of MS, AI has introduced revolutionary advancements that have transformed how the disease is detected and monitored. These advancements have brought about numerous benefits, enhancing both the accuracy and efficiency of MS diagnosis and management. However, it's crucial to consider ocular complications associated with MS, as they can impact the interpretation of SLO images.

changes in retinal appearance. Similarly, intermediate uveitis affects the middle layer of the eye (uvea), potentially causing opacity and inflammation in the vitreous, which can be visualized through SLO imaging.

Despite these ocular manifestations, our study did not explicitly address the ocular involvement of MS cases. Including information about ocular complications in MS patients could provide additional context to our study findings and enhance the comprehensiveness of our article.

Numerous studies have been undertaken to ascertain the diagnosis of individuals with (MS). In [14] employed optical coherence tomography angiography (OCTA), coupled with machine learning algorithms, to study retinal blood vessels in MS patients. Their results revealed significant micro vascular alterations in the retinas of MS patients, suggesting a potential link between retinal vascular changes and MS progression. The study demonstrated a moderate precision in identifying retinal vessel abnormalities (Precision: 0.85).

In [15], utilized fundus photography alongside CNNs to analyze retinal blood vessels in MS patients. They identified subtle vascular changes that correlated with disease severity. Despite the non-invasive nature of the method, the study had limited spatial resolution, affecting the accuracy of vessel characterization (Precision: 0.78). In [16] employed a longitudinal study design and adaptive optics scanning laser ophthalmoscopy (AOSLO), along with deep learning models, to investigate retinal micro vascular changes in MS patients. Their findings indicated progressive capillary loss, contributing to visual dysfunction. The study's advantage lay in its high-resolution imaging, but the sample size was relatively small (Precision: 0.91). In [17] employed fluorescein angiography to examine retinal blood flow alterations in MS patients, incorporating artificial neural networks for data analysis. They found evidence of impaired retinal perfusion in MS patients compared to controls. The technique provided dynamic

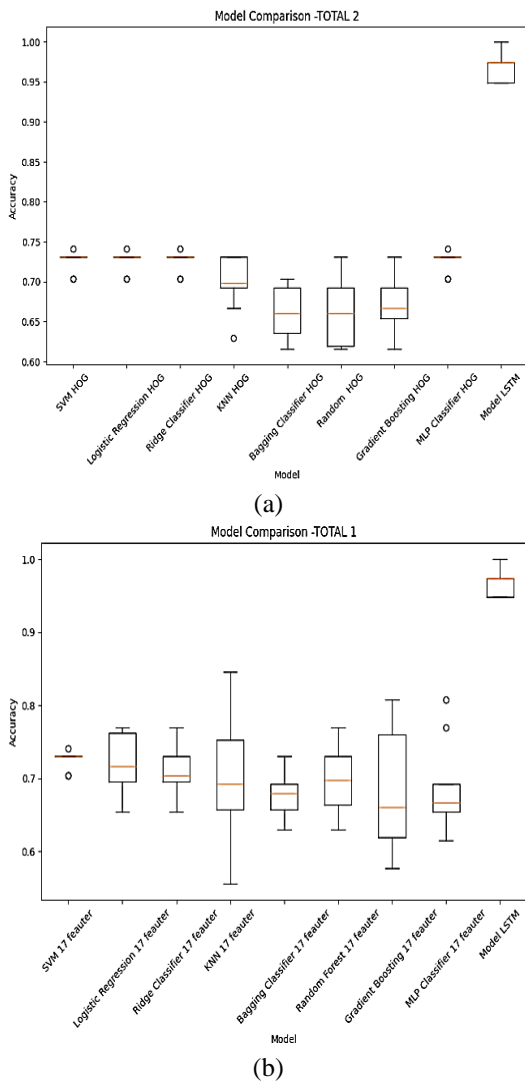


Fig. 8. compare the validation with LSTM different Machine Learning models for HOG (a) compare the validation with LSTM different Machine Learning models for 17 features (b)

Some types of MS diseases, such as intermediate uveitis or optic neuritis, manifest with ocular complications that affect SLO ophthalmoscopy appearance. For instance, optic neuritis involves inflammation of the optic nerve, leading to visual disturbances and

vascular information but was invasive and carried potential risks (Precision: 0.92).

In [18], utilized a combination of LSTM and magnetic resonance imaging (MRI) alongside machine learning algorithms to assess retinal blood vessels and brain lesions in MS patients. They identified associations between retinal vessel density and white matter lesion volume, providing insights into disease pathophysiology. The study's integration of imaging modalities enhanced its comprehensive analysis (Precision: 0.89). In [19] conducted a cross-sectional study using Doppler optical coherence tomography (D-OCT), incorporating artificial intelligence techniques for flow analysis, to investigate retinal blood flow in MS patients. They observed reduced retinal venous flow velocity in MS patients, indicating potential vascular impairment. The method's non-invasiveness was advantageous, but the study lacked longitudinal data (Precision: 0.88). In [20] employed infrared imaging and OCTA, integrating machine learning algorithms, to assess retinal vessel density in pediatric MS patients. Their results revealed early micro vascular alterations, suggesting potential markers for disease onset. The study's focus on the pediatric population added a unique dimension to MS research (Precision: 0.93). In [21] used a retrospective approach, analyzing medical records and imaging data to correlate retinal vessel changes with clinical parameters in MS patients. They found associations between vessel abnormalities and disability scores, contributing to the understanding of disease progression. The study's reliance on existing data limited its ability to control for confounding variables (Precision: 0.76).

In [22] utilized advanced image analysis techniques on OCTA data, incorporating machine learning for vessel density quantification, to quantify retinal vascular density in MS patients. They demonstrated reduced vessel density in MS patients, suggesting a potential marker for disease severity. The study's quantitative approach enhanced its precision, although the imaging data's variability posed challenges (Precision:

0.94). In [23] employed a multi-modal imaging approach, combining OCTA with micro perimetry, along with machine learning algorithms, to assess retinal vascular and functional changes in MS patients. They identified correlations between retinal sensitivity and vessel density, highlighting the impact of vascular alterations on visual function. The study's integration of functional data provided valuable insights (Precision: 0.90). In [24] used a prospective design to study retinal vessel changes in MS patients using OCTA, incorporating AI-driven segmentation algorithms. They observed vessel density reductions in both superficial and deep retinal plexuses, suggesting a comprehensive vascular involvement. The longitudinal approach enhanced the study's ability to track changes over time (Precision: 0.96).

To evaluate the performance of the proposed model, we compare the accuracy of this work with previous works, the results of which are in Fig. 9.

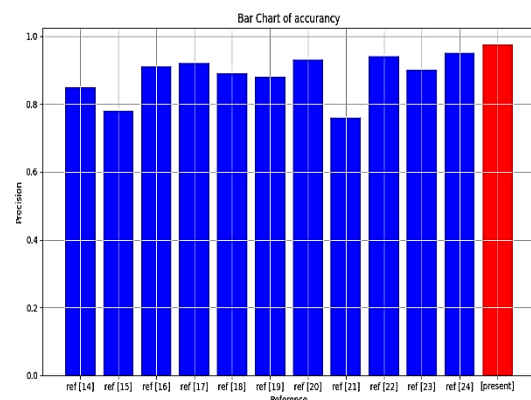


Fig. 9. Comparison the accuracy of present study with previous works

Overall, the proposed method demonstrated the potential of deep learning techniques for automatic classification of SLO images, which could have applications in the diagnosis and monitoring of ocular diseases. Further research is needed to optimize and validate this approach for clinical use.

## V. CONCLUSION

By conducting experiments on the SLO data set and using the proposed method based on vessels and LSTM, the experimental results

show that this high-accuracy approach helps in the early detection of multiple sclerosis. These models have the ability to diagnose diseases with high accuracy and appropriate sensitivity.

Using the approach based on vessels and LSTM in the diagnosis of multiple sclerosis has many potentials and applications. One of these applications is the early diagnosis of the disease, which allows for faster treatment and prevents the progression of the disease. Also, this method can be used as an auxiliary tool to investigate and evaluate the effect of different treatments.

In this paper, a vessel-based approach for multiple sclerosis detection in SLO images using LSTM networks was investigated. Experimental results show that this high-precision approach helps to diagnose multiple sclerosis and can be effective in early diagnosis of the disease and improving the quality of patient care.

The use of deep learning models such as LSTM in the diagnosis of multiple sclerosis has many advantages, but also comes with challenges. Improving the interpretability of models, increasing the accuracy of diagnoses and conducting experiments with different populations are among the future research directions that will provide more improvement and productivity of this approach.

### Ethical Statement

Collecting this dataset was approved by the ethics committee of Isfahan University of Medical Sciences and was conducted according to the Declaration of Helsinki in the applicable version.

All authors declare that they have no conflicts/competing of interest.

### ACKNOWLEDGMENT

First author would like to extend her heartfelt appreciation to her esteemed professors for their important demonstration of patience, direction, and criticism during the course of this research endeavor. The experience and knowledge possessed by the individuals in

question have played a crucial role in developing the present research. Furthermore, she would want to express her gratitude to those individuals who have graciously offered their support and aid in many facets of our endeavor.

First author would like to express her gratitude to her family, with particular emphasis on her parents, husband, and kid, for their consistent support and encouragement during the whole of this endeavor. The unwavering faith that others have placed in her abilities has always served as a driving force and a wellspring of creative influence.

### REFERENCES

- [1] N. Young, R. Zivadinov, M.G., Dwyer, N. Bergsland, B., Weinstock-Guttman, and D. Jakimovski, "Retinal Blood Vessel Analysis Using Optical Coherence Tomography (OCT) in Multiple Sclerosis," *Diagn.*, Vol. 13, no. 4, pp. 596, 2023.
- [2] D. Costin, G.M. Pinzaru, A.M. Pătrașcu, A. Moțoc, and A.D. Moraru, "Multiple sclerosis with ophthalmologic onset - case report," *Rom J. Ophthalmol.*, Vol. 62, no. 1, pp. 78–82, 2018.
- [3] J. Chua, M. Bostan, C. Li, Y. C. Sim, I. Bujor, D. Wong, B. Tan, X. Yao, and F. Schwarzshans, "A multi-regression approach to improve optical coherence tomography diagnostic accuracy in multiple sclerosis patients without previous optic neuritis," *NeuroImage, Clin.*, Vol. 34, pp. 103010(1-8), 2022.
- [4] B. Mihaylova and S. Cherninkova, "Optical Coherence Tomography (OCT) and Angio-OCT Imaging Techniques in Multiple Sclerosis Patients with or without Optic Neuritis," in *Multiple Sclerosis-Genetics, Disease Mechanisms and Clinical Developments*, IntechOpen, pp. 105772-106585, 2022.
- [5] Z. Khodabandeh, H. Rabbani, F. Ashtari, H.G. Zimmermann, S. Motamedi, A.U. Brandt, F. Paul, and R. Kafieh, "Interpretable classification using occlusion sensitivity on multilayer segmented OCT from patients with Multiple Sclerosis and healthy controls," pp. 1-16, <https://doi.org/10.21203/rs.3.rs-1547669/v1>, 2022.
- [6] M. Eslami, S. Lichtman-Mikol, S. Razmjou, and E. Bernitsas, "Optical Coherence Tomography in Chronic Relapsing

- Inflammatory Optic Neuropathy, Neuromyelitis Optica and Multiple Sclerosis: A Comparative Study,” *Brain Sci.*, Vol. 12, no. 9, pp. 1140(1-11), 2022.
- [7] T. Pearson, Y. Chen, B. Dhillon, S. Chandran, J. van Hemert, and T. MacGillivray, “Multi-modal retinal scanning to measure retinal thickness and peripheral blood vessels in multiple sclerosis,” *Sci. Rep.*, Vol. 12, no. 1, pp. 20472-20486, 2022.
- [8] E. El-Mayah, M.M.A. Mohamed, H. Elmekawey, and R.M. Eltanamly, “Correlation between retinal and optic nerve microvasculature and sensitivity in patients with multiple sclerosis with and without optic neuritis,” *J. Egypt. Ophthalmol. Soc.*, Vol. 115, no. 4, pp. 222-231, 2022.
- [9] H. Jiang, G.R. Gameiro, Y. Liu, Y. Lin, J. Hernandez, Y. Deng, G. Gregori, S. Delgado, and J. Wang, “Visual function and disability are associated with increased retinal volumetric vessel density in patients with multiple sclerosis,” *Am. J. Ophthalmol.*, Vol. 213, pp. 34-45, 2020.
- [10] J. Fischer, T. Otto, F. Delori, L. Pace, and G. Staurenghi, *Scanning laser ophthalmoscopy (SLO): High resolution imaging in microscopy and ophthalmology: new frontiers in biomedical optics*, pp. 35-57, 2019.
- [11] A. Karkehabadi, P. Oftadeh, D. Shafaie, and J. Hassanpour, “On the Connection between Saliency Guided Training and Robustness in Image Classification,” *Proc. 12th Int. Conf. on Intelligent Control and Information Processing (ICICIP)*, Nanjing, China, pp. 203-210, 2024.
- [12] H. Xie, “AMD-GAN: Attention encoder and multi-branch structure based generative adversarial networks for fundus disease detection from scanning laser ophthalmoscopy images,” *Neural Netw.*, Vol. 132, pp. 477-490, 2020.
- [13] M.A. Mainster, “Scanning laser ophthalmoscopy retro illumination: Applications and illusions,” *Int. J. Retina Vitreous*, Vol. 8, no. 1, pp. 1-9, 2022.
- [14] M.M. Fraz, “Blood vessel segmentation methodologies in retinal images—a survey,” *Comput. Methods Programs Biomed.*, Vol. 108, no. 1, pp. 407-433, 2012.
- [15] A. Karkehabadi and A. Sasan, “SMOOT: Saliency guided mask optimized online training,” *ArXiv preprint arXiv:2310.00772*, 2023.
- [16] A. Desiani, “VG-Drop Net: A robust architecture for blood vessels segmentation on retinal image,” *IEEE Access*, Vol. 10, pp. 92067-92083, 2022.
- [17] H. Wilhelm and M. Schabet, “The diagnosis and treatment of optic neuritis,” *Dtsch. Arztebl. Int.*, Vol. 112, no. 37, pp. 616-627, 2015.
- [18] B. Bhaduri, “Detection of retinal blood vessel changes in multiple sclerosis with optical coherence tomography,” *Biomed. Opt. Express*, Vol. 7, no. 6, pp. 2321-2330, 2016.
- [19] R.I. Spain, L. Liu, X. Zhang, Y. Jia, O. Tan, D. Bourdette, and D. Huang, “Optical coherence tomography angiography enhances the detection of optic nerve damage in multiple sclerosis,” *Br. J. Ophthalmol.*, Vol. 102, no. 4, pp. 520-524, 2018.
- [20] C. Cavaliere, “Computer-aided diagnosis of multiple sclerosis using a support vector machine and optical coherence tomography features,” *Sensors*, Vol. 19, no. 23, pp. 5323-5332, 2019.
- [21] A. Montolío, J.O.S.E. CEGONino, E. GarciaMartin, and A. Pérez del Palomar, “Comparison of machine learning methods using spectralis OCT for diagnosis and disability progression prognosis in multiple sclerosis,” *Ann. Biomed. Eng.*, Vol. 50, no. 5, pp. 507-528, 2022.
- [22] R.C. Kenney, M. Liu, L. Hasanaj, B. Joseph, A. Abu Al-Hassan, L.J. Balk, R. Behbehani, A. Brandt, P.A. Calabresi, E. Frohman, T.C. Frohman, J. Havla, B. Hemmer, H. Jiang, B. Knier, T. Korn, L. Leocani, E.H. Martinez-Lapiscina, A. Papadopoulou, F. Paul, A. Petzold, M. Pisa, P. Villoslada, H. Zimmermann, L.E. Thorpe, H. Ishikawa, J.S. Schuman, G. Wollstein, Y. Chen, S. Saidha, S. Galetta, and L.J. Balcer, “The role of optical coherence tomography criteria and machine learning in multiple sclerosis and optic neuritis diagnosis,” *Neurol.*, Vol. 99, no. 11, pp. 1100-1112, 2022.
- [23] A. López-Dorado, J. Pérez, M.J. Rodrigo, J.M. MiguelJiménez, M. Ortiz, L. de Santiago, E. LópezGuillén, R. Blanco, C. Cavaliere, E.M.S. Morla, L. Boquete, “Diagnosis of multiple sclerosis using multifocal ERG data feature fusion,” *Inf. Fusion*, Vol. 76, pp. 157-167, 2021.

[24] M. Bakhshi, A. Karkehabadi, and S.B. Razavian, "Revolutionizing Medical Diagnosis with Novel Teaching-Learning-Based Optimization," in Proc. Int. Conf. on Emerging Smart Computing and Informatics (ESCI), IEEE, pp. 1-6, March 2024.

[25] N. Yaghoubi, H. Masumi, M.H. Fatehi, F. Ashtari, R. Kafieh, "Deep learning and classic machine learning models in the automatic diagnosis of multiple sclerosis using retinal vessels," *Multimed. Tools Appl.*, Advance online publication, DOI: 10.1007/s11042-023-16812-w, Vol. 83, pp. 37483–37504, 2023.

[26] A. Abraham, L. Nicholson, A. Dick, C. Rice, D. Atan, "Intermediate uveitis associated with MS: Diagnosis, clinical features, pathogenic mechanisms, and recommendations for management," *Neurol. Neuroimmunol. Neuroinflamm.*, Vol. 8, no. 1, pp. 909-915, 2021.



**Neda Yaghoubi** received her B.Sc. in biomedical engineering from Azad University of Mashhad, M.Sc. in biomedical engineering from Azad University of Kazerun, and Ph.D. in biomedical engineering from Azad University of Kazerun, Iran. Her research interests are in biomedical image analysis, pattern recognition, classification, and image segmentation.



**Hassan Masumi** received her B.Sc. in electrical and electronics engineering from Azad University (2001-2005), M.Sc. in image and signal processing, industrial automation, from Azad University, (2006-2008), and Ph.D. at Azad University, Iran. He is an Associate professor in the Department of Biomedical Engineering, Islamic Azad University, Kazerun, Iran.



**Mohammad Hossein Fatehi** received his Ph.D. in electrical engineering (control). He is an associate professor at Department of Electrical Engineering, Islamic Azad University, Kazerun, Iran.



**Fereshteh Ashtari** is a neurologist and professor at Isfahan Neurosciences Research Center, Isfahan University of Medical Sciences, Iran.



**Rahele Kafieh** received her BSc in bioelectrical engineering from Sahand-University of Technology (2004) and completed her MSc and Ph.D. in bioelectrical engineering at Isfahan University of Medical Sciences (2008 and 2014). She is an assistant professor at the School of Advanced Technologies in Medicine, Isfahan University of Medical Sciences, Isfahan, Iran, and a research associate at Biosciences Institute, Newcastle University, and Newcastle upon Tyne, UK. Her research is concentrated on biomedical image analysis, problems in the area of graph-based image analysis, time-frequency methods, deep learning, and image segmentation.